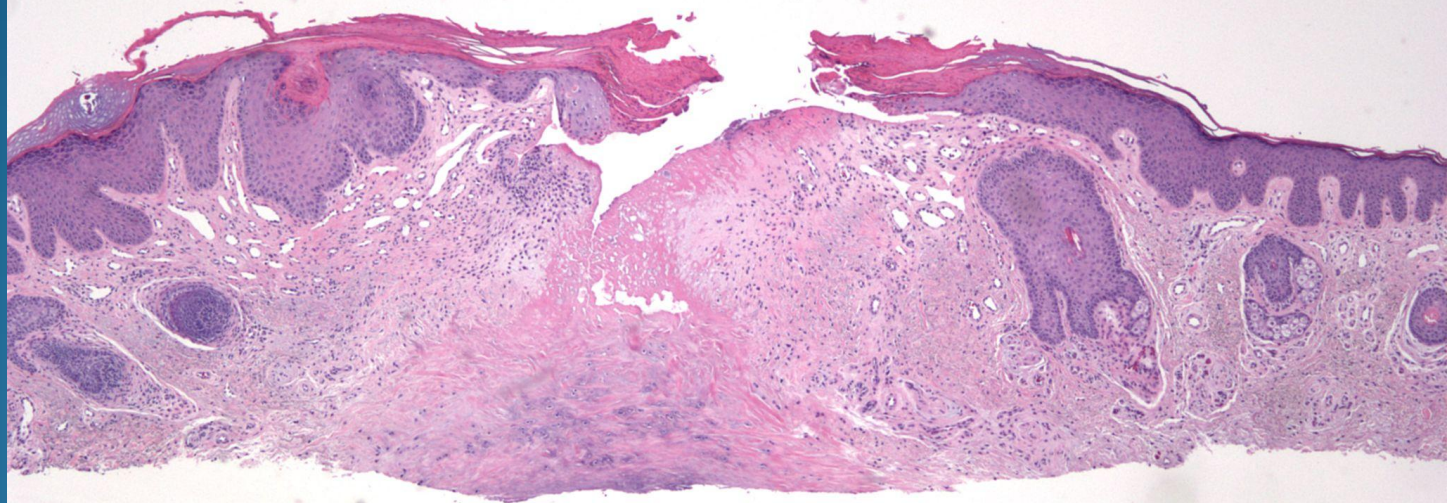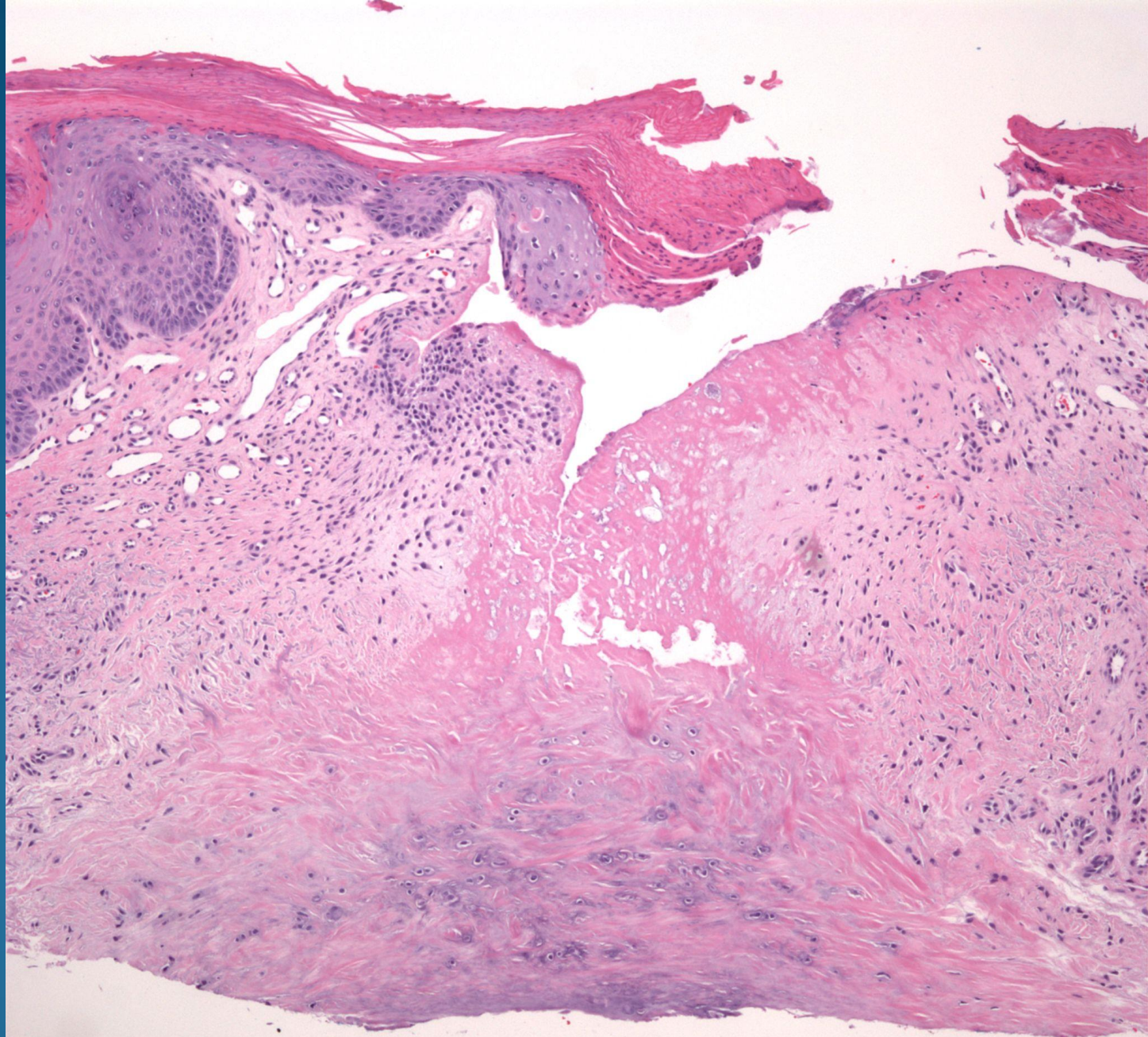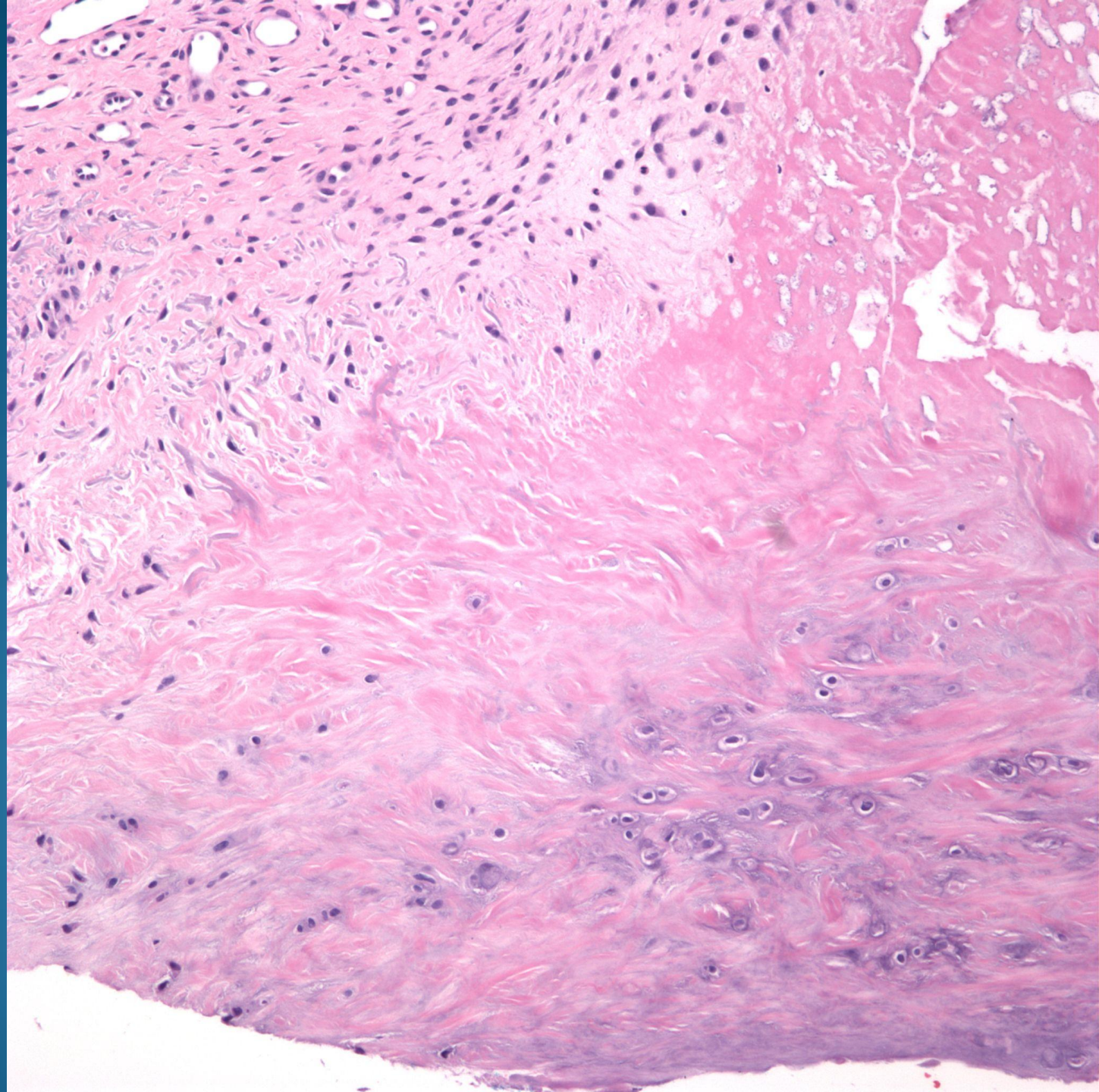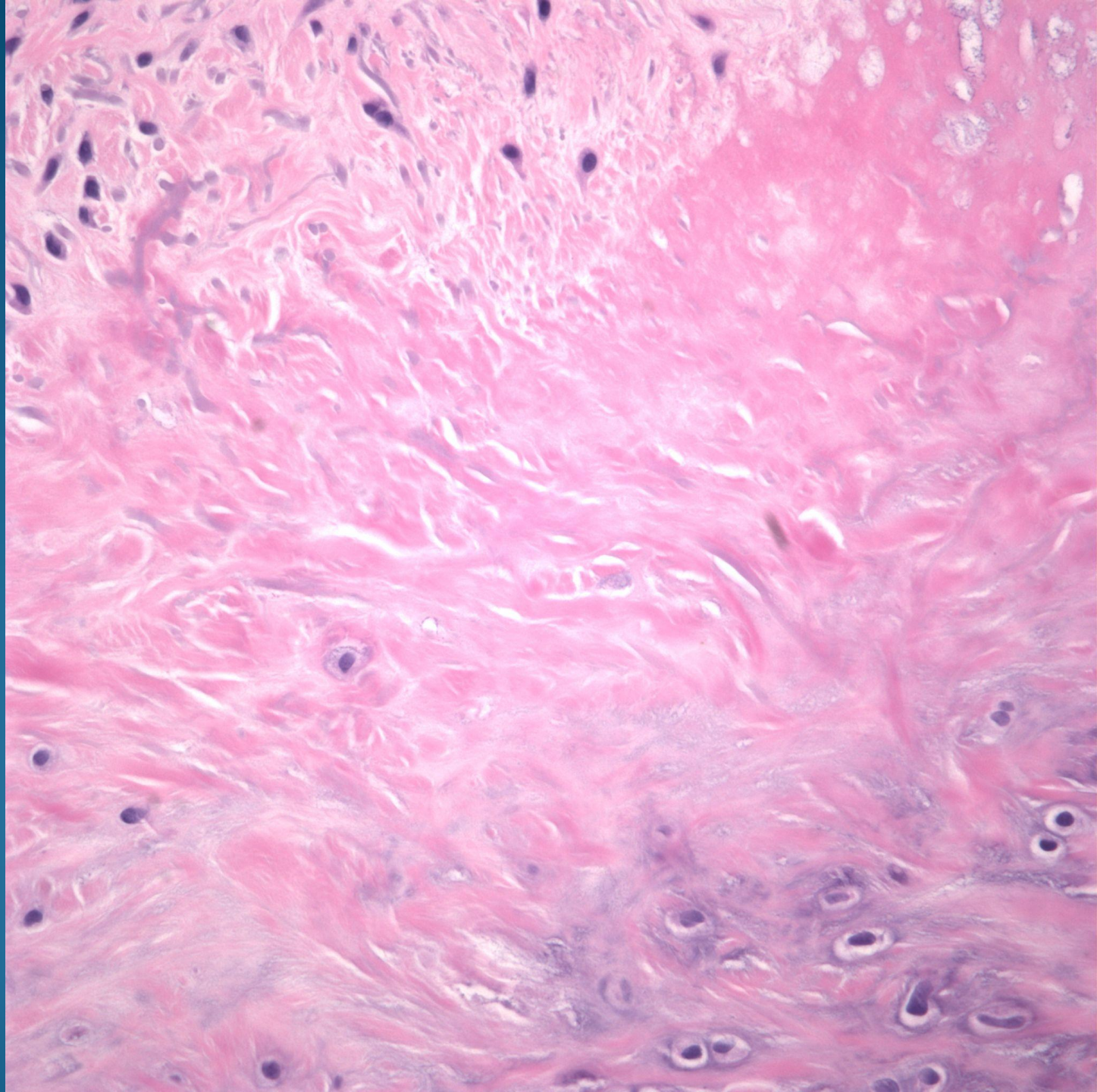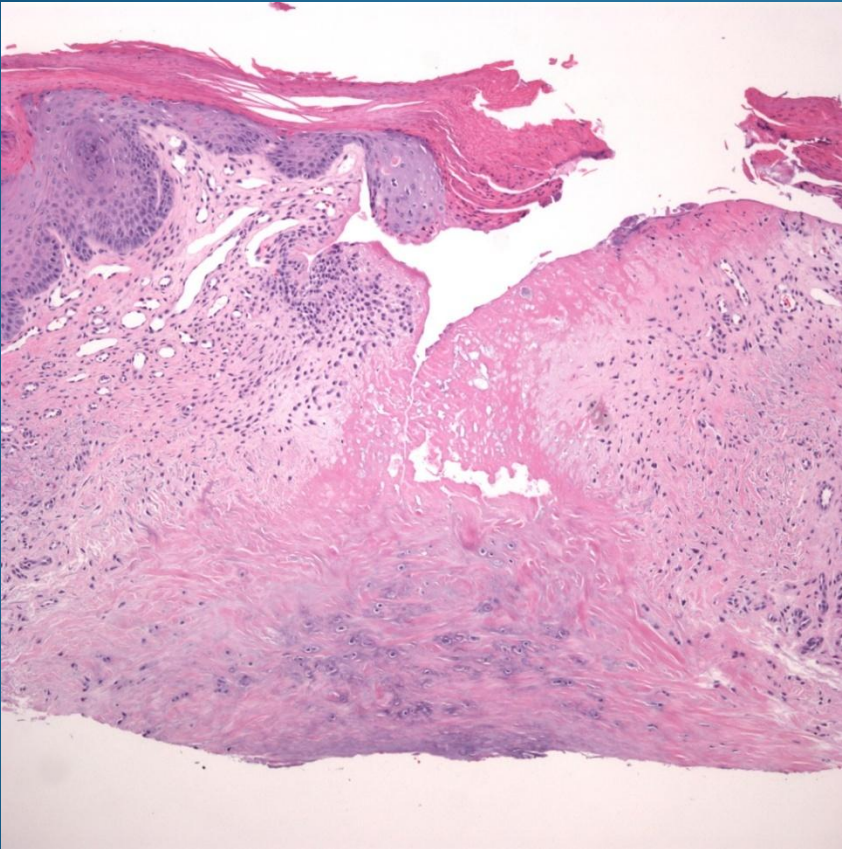


Chondrodermatitis nodularis helicis

Pearls



- Eosinophilic collagen and degenerating cartilage
- May have epidermal hyperplasia or ulceration
- Occasionally, may only see proliferating perichondrocytes
- Rule out relapsing polychondritis and underlying connective tissue disease